

Change View Capture Add Patient Find Patient Start Capture

Ceph Tool...

**Tracing Panel**

View / Select

- X-Ray
- Tracing

Tracing

Delete selection

Operations

Ceph Tracing

Treatment Plan

View

Analysis: **DOWNNS**

Configuration

Layer: **Layer 1**

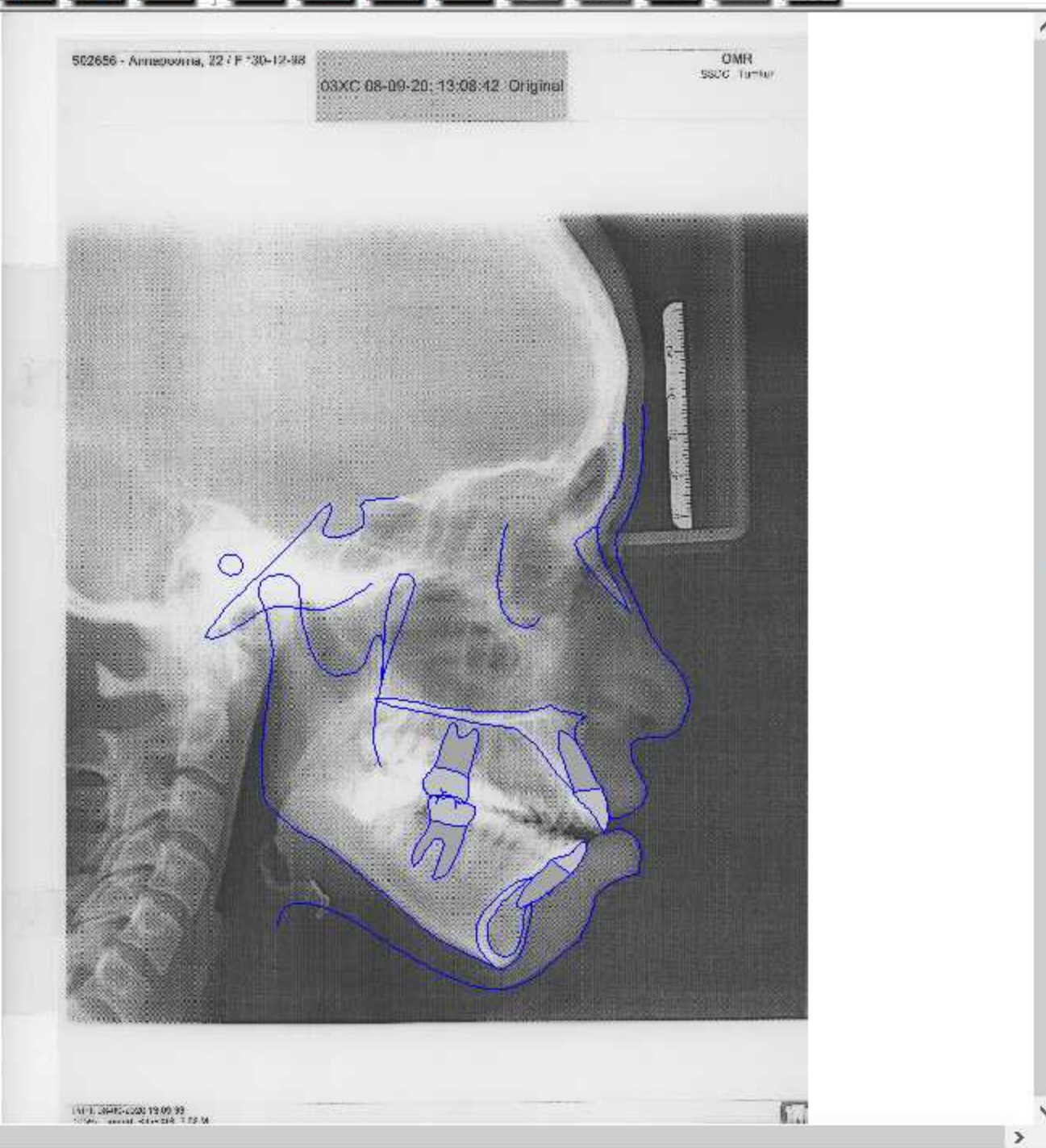
Tracing  Profile

Control points  Morphing

Low contrast **VERT**

Areas: Anchrage

View Color/Lines config



**Tracing measurements**

Downs Analysis

Save and Delete

Measurement	Active	Dev. Unit
Dental Pattern		
Lower I - Mandibu...	<b>101.6°</b>	xxx
Lower I - Occlusal ...	<b>27.1°</b>	xx
Interincisal angle	<b>109.9°</b>	-xxx
Upper Incisor protr...	<b>11.7</b>	xxx
Skeletal Pattern		
A-B to Facial Plane	<b>5.3°</b>	N
Convexity	<b>9.8°</b>	N
Facial Angle	<b>94.2°</b>	x
Mandibular Plane ...	<b>20.5°</b>	N
Facial Axis	<b>90.3°</b>	N

Copy to Clipboard Copy to Disk Details

**Find Patient**

Patient selected

Name: Annapurna

Surname: A

Code: 502656

Status: Pretreatment

New Search Search

**Search results**

St...	C...	Name
Pr...	47...	. Umadevi
Pr...	84...	a Abhishek
Pr...	50...	A Annapurna
Pr...	50...	<b>A Annapurna</b>
Pr...	17...	A N DEVIKA
Pr...	42...	A Thejas
Pr...	FF	AF aYEHAA
Pr...	27...	asde Harsha
Pr...	19...	ASHOK ATHULYA
Pr...	32...	B ASHA
Pr...	36...	B Eshwar
Pr...	54...	b varshini
Pr...	30	C ANUSHA R
Pr...	87...	c pooja
Pr...	42...	D Prashanthi
Pr...	34...	D RESHMA
Pr...	47...	d s umashankar
Pr...	47...	D S Umashankar
Pr...	28	e Nayana BN
Pr...	25	fg shahana
Pr...	83...	fr Greeshama
Pr...		fss zsff
Pr...	00...	G R YOGESH
Pr...	21...	G RAGESHA
Pr...	56...	g varsha

Open patient